



Management of Ewing Family of Tumors Arising from Chest Wall in Children

İdil Rana User¹, Burak Ardıçlı¹, Arbay Özden Çiftçi¹, İbrahim Karnak¹, Berna Oğuz², Mithat Haliloğlu², Tezer Kutluk³, Ferah Yıldız⁴, Diclehan Orhan⁵, Filiz Üzümcügil⁶, Saniye Ekinci¹

¹Hacettepe University Faculty of Medicine, Department of Pediatric Surgery, Ankara, Turkey

²Hacettepe University Faculty of Medicine, Department of Pediatric Radiology, Ankara, Turkey

³Hacettepe University Faculty of Medicine, Department of Pediatric Oncology, Ankara, Turkey

⁴Hacettepe University Faculty of Medicine, Department of Radiation Oncology, Ankara, Turkey

⁵Hacettepe University Faculty of Medicine, Department of Pathology, Ankara, Turkey

⁶Hacettepe University Faculty of Medicine, Department of Anesthesiology and Reanimation, Ankara, Turkey

ABSTRACT

Aim: Malignant chest wall tumors are rare in children. We aimed to study the management of the Ewing family of tumors (EFT) in the chest walls of children.

Materials and Methods: The files of patients diagnosed with primitive neuro-ectodermal tumor and Ewing sarcoma of the chest wall in the prior 2 decades were retrospectively reviewed.

Results: A total of 15 children with a median age of 10 (8-14) years were included. Their symptoms were palpable mass (n=6), chest pain (n=4), B symptoms (n=2), cough (n=2) and abdominal pain. Their history revealed delayed diagnoses in 1/3 of the patients due to a misinterpretation of the symptoms. All children except for one had tru-cut biopsy and upfront chemotherapy. The median greatest diameter of mass at diagnosis was 100 (67-148) mm and 51 (39-100) mm at preoperative imaging after chemotherapy. Pleural effusion (n=8), costal destruction (n=9), extension to neural foramina (n=3), pulmonary or diaphragmatic nodule (n=5) and distant bone metastasis (n=4) were present at diagnosis in some cases. More than one surgery was performed in 9 (60%) of the children in order to remove the primary tumor and metastases. Costal excision (n=11), diaphragmatic resection (n=6) and chest wall reconstruction with graft material were performed on 8 patients. All cases had radiotherapy postoperatively. Mortality occurred in 9 (60%) patients due to local recurrences or metastases. Only 3 children reached 5-year survival and were considered to be cured. The remaining 3 patients completed their first line oncologic treatments and were under surveillance without treatment.

Conclusion: The EFT in the chest wall are aggressive tumors with poor prognosis despite multimodality treatment. Surgeons dealing with these patients should be familiar with complex chest wall reconstruction techniques.

Keywords: PNET, Ewing sarcoma, chest wall, child

Address for Correspondence

İdil Rana User, Hacettepe University Faculty of Medicine, Department of Pediatric Surgery, Ankara, Turkey

Phone: +90 533 560 25 15 E-mail: idilranau@gmail.com ORCID: orcid.org/0000-0003-2763-388X

Received: 25.03.2024 Accepted: 10.05.2024



Copyright© 2024 by Ege University Faculty of Medicine, Department of Pediatrics and Ege Children's Foundation.
The Journal of Pediatric Research, published by Galenos Publishing House.
Licensed under a Creative Commons Attribution-NonCommercial-NoDerivatives 4.0 International License (CC BY-NC-ND 4.0).

Introduction

Chest wall tumors are rare in childhood, comprising only 2% of all childhood malignancies. Most of them are soft tissue sarcomas or tumors arising from bony or cartilaginous tissues of the chest wall (1). Peripheral primitive neuro-ectodermal tumor (PNET) and Ewing sarcoma are very similar tumors in terms of their histology, biology and clinical presentation and they are collectively known as the Ewing family of tumors (EFT) (2). Most of the tumors arising from the chest wall in childhood belong to this family of tumors. They show aggressive and infiltrative behavior but are also chemo- and radio-sensitive (3). Treatment is multidisciplinary, which is similar to most of the pediatric solid tumors. Neoadjuvant chemotherapy followed by surgery and radiotherapy is the standard treatment approach. Recurrences and metastasis are common in these patients and they are managed by second line treatments and palliative interventions. The huge diameters and infiltrative growth patterns of these tumors demand extensive resections and reconstructive surgical applications. In this study, we aimed to present our experiences with this rare tumor of childhood from a pediatric surgical oncology standpoint.

Materials and Methods

This study covered patients admitted to a pediatric surgery clinic during the previous 2 decades with a diagnosis of PNET and Ewing sarcoma. The patient list was derived from the institutional tumor registry of the hospital electronic database. The selected patient files were reviewed retrospectively for age, gender, presenting symptoms, computed tomography reports, surgical details and pathology results. All cases in this cohort were evaluated, treated and followed by a team of physicians from the pediatric surgery, radiology, pathology and oncology departments which are dedicated to the care of pediatric oncology and oncologic surgery patients. The management algorithm is as follows: tru-cut biopsy followed by 6 cycles of induction chemotherapy, surgical excision and adjuvant chemotherapy and radiotherapy. The patients in this study were treated according to the European Ewing regimen, specifically Arm A, which consists of VIDE (vincristine, ifosfamide, doxorubicin, and etoposide) induction therapy followed by VAC (vincristine, actinomycin D, and cyclophosphamide) consolidation therapy.

This study was approved by the Hacettepe University Non-interventional Clinical Research Ethics Board (approval no.: 2022/22-10, date: 27.12.2022).

Statistical Analysis

The statistical analyses were performed with SPSS software (version 22.0). Two-tailed p-values <0.05 were considered statistically significant. Continuous variables are presented as median (interquartile range-IQR) because of their non-normal distribution.

Results

A total of 15 children (10 female, 5 male) were diagnosed with PNET/Ewing sarcoma of the chest wall during the study period. The median age of the patients was 10 (8-14) years. The presenting symptoms were palpable mass in 6 cases, chest pain in 4, B symptoms in 2, cough in 2 and abdominal pain in one patient. History revealed delayed diagnosis in 1/3 of the patients due to misinterpretations of the symptoms. At the time of diagnosis, 12 patients had positron emission tomography computed tomography which showed long bone metastasis in 3, lymph node metastasis in one and bone marrow infiltration in another patient. Fluorodeoxyglucose uptake limited to the primary tumor was the case in 7 patients. Median greatest diameter of mass at diagnosis was 100 (67-148) mm and 51 (39-100) mm at preoperative imaging after chemotherapy. The mass was located posteriorly in 8, laterally in 6 and anteriorly in one patient (Table I). Imaging studies revealed costal destruction in 9 cases (Figure 1), pleural effusion in 8, pulmonary or diaphragmatic involvement in 5 and extension to neural foramina in 3 patients. All of the children except one had tru-cut biopsy at the time of diagnosis and received upfront chemotherapy. More than one surgery was performed on 9 (60%) children in order to remove the primary tumor, its metastases or recurrences. Costal resection was carried out in 11 patients and the median number of resected ribs was 3 (1-3). The chest wall was reconstructed with ePTFE graft material in 8 out of the 11 patients who had more than one costal excision. To ensure en bloc resection, pulmonary tissue adjacent to the tumor was resected in 8 cases and diaphragmatic resection was performed in 6 cases. In all cases, gross total resection without macroscopic residue was achieved. The postoperative period was uneventful and the median hospital stay was 7 (6-10) days. Pathologic examination of the resected tumor showed diffuse histologic changes secondary to treatment in 11 patients and >95% necrosis in 5 individuals. Surgical margins were positive in 10 patients. FISH study was positive for Ewing sarcoma breakpoint region 1 (EWSR1) translocation in 10 out of 11 patients.

Table 1. Clinical characteristics of patients at the time of diagnosis

Age (median, years)	10 (8-14)
Sex	
Male	5
Female	10
Side	
Right	7
Left	8
Location	
Anterior	1
Posterior	8
Lateral	6
Presenting symptom	
Palpable mass	6
Chest pain	4
B symptoms	2
Cough	2
Abdominal pain	1
Metastasis	
Pulmonary nodule	4
Bone	3
Bone marrow	1
Lymph node	1

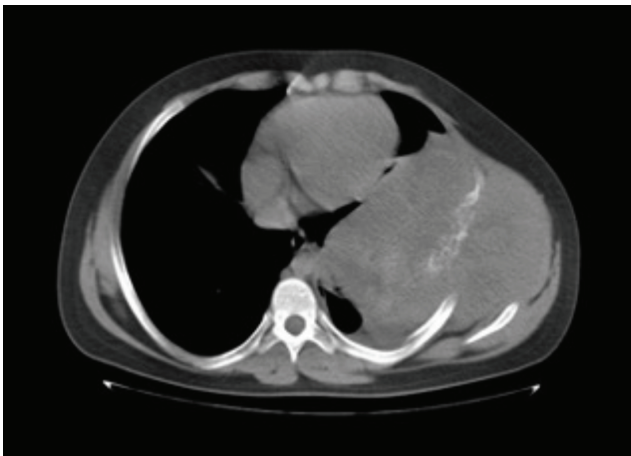


Figure 1. 14-year-old boy with PNET. Axial non-contrast computed tomography scan demonstrates an extra-pleural giant heterogeneous solid mass causing osseous destruction of the left lateral 6th rib. The mass extends into the left chest wall and hemithorax

All cases received radiotherapy and chemotherapy in the postoperative period. The mortality rate was 60%. The cause of death was distant metastasis in 5, local recurrences

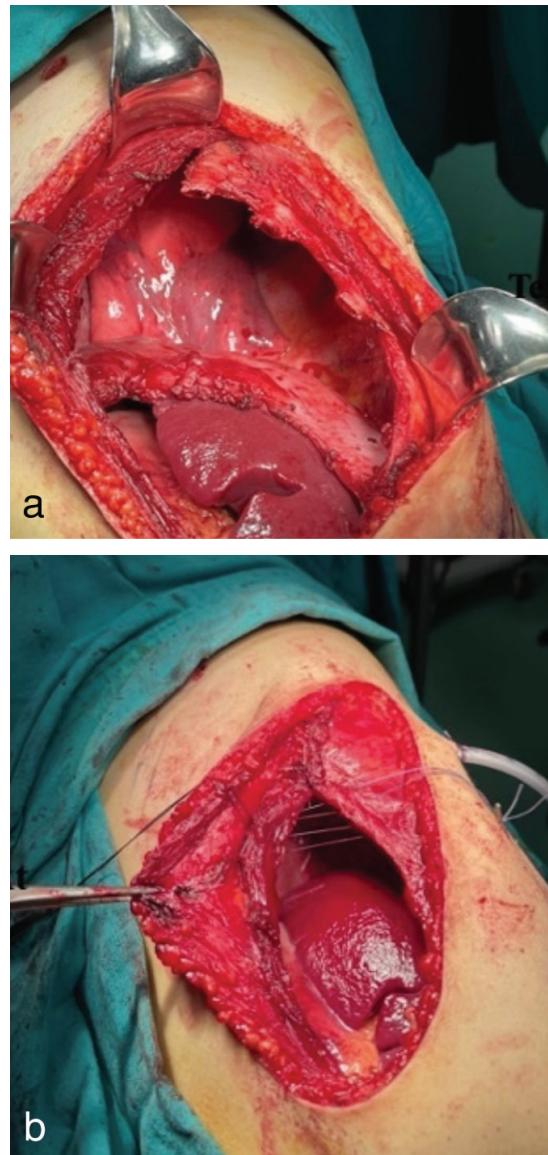


Figure 2. Intraoperative image of the chest wall tumor resection which infiltrates the lower ribs, intercostal muscles and diaphragm (a) and primary reconstruction (b)

in 3 and secondary leukemia in one patient. Only 3 children reached 5-year survival and were considered to be cured. The remaining 3 patients completed their treatment and were under close surveillance. There were no long-term complications such as scoliosis or posture abnormality in those patients who survived the disease.

Discussion

Malignant tumors arising from the chest wall are very rare in childhood and Ewing sarcoma/PNET is the most common diagnosis in these patients. They arise from bony structures, muscles or connective tissue but tend to grow

in an infiltrative pattern affecting various tissues. The main surgical aim should be total resection without macroscopic residue as in all cases of sarcomas (1). Due to these features, surgery involves the resection of different tissues and the reconstruction of a functioning chest wall. Experience is limited in this patient group since they constitute only 2% of childhood malignancies (4). We reviewed our experiences in the management of EFT arising from the chest wall in children.

EFT at the time of diagnosis are usually huge in diameter with costal, pleural, muscular, adjacent pulmonary or diaphragmatic invasion and extension to spinal foramen. Surgical resection should be deferred until after the induction chemotherapy (5). Treatment-induced size reduction may allow for less extensive resection and a higher rate of negative margins. A fifty percent reduction in the greatest diameter was achieved with neoadjuvant chemotherapy in our patients. This finding was compatible with previous data (2,4). In addition, chemotherapy should be employed upfront to treat occult metastatic foci and circulating tumor cells (3).

Surgical resection and the reconstruction of the chest wall is a formidable challenge in children. Their growing body size and long life expectancy distinguish children from adults. There are various materials which can be employed to cover defects in the chest wall when we resect components of the chest wall neighboring a tumor. There are synthetic, biologic and metallic prosthetic materials which are used to cover defects in the chest wall and each have different properties (4-6). In cases of malignant tumor resection, the graft material should be compatible with radiotherapy, suitable for re-entrance for surgery since these tumors tend to recur and possess some amount of flexibility in order to adapt to a growing thoracic wall (5-7). We prefer ePTFE mesh in our practice. It integrates well into the thoracic wall showing minimal tissue reaction. Also, all patients had radiotherapy on the surgical field in the postoperative period. Scoliosis is a well-known long-term complication in patients with chest wall resection (8). Due to the low life expectancy and complete cure rates in our group, we could not deduce any statistically significant information regarding this issue.

The risk of local recurrence and distant metastasis remains high in the EFT despite advances in all aspects of oncologic treatments. Histologic response to neoadjuvant chemotherapy is an indicator of prognosis in these patients. Good histologic response is defined by the degree of necrosis and >95% is generally acceptable (3). We observed this

amount of necrosis in only 1/3 of our patients and assumed that it was one of the major contributors to the high mortality rate in our cohort. Another issue is to achieve negative surgical margins in sarcoma patients (3). Even though aggressive surgical resection involving the full thickness of the chest wall, pulmonary and diaphragmatic resections, the surgical margins were positive microscopically in the majority of our patients which implies a high possibility of local recurrence. The posteriorly location of the tumor and a tumor diameter >10 cm at diagnosis are associated with poor prognosis (1,9). More than half of our patients had posteriorly located tumors and >10 cm diameter at the time of diagnosis. The largest study regarding the outcome in Ewing sarcoma and PNET including 3,575 patients derived from the SEER database revealed a 5-year survival rate of slightly above 50%. However, this cohort included cases of all anatomic locations, not just exclusive to the chest wall (2).

Study Limitations

Main limitation of our study was its small sample size. Multi-centric studies should be designed in order to recruit more patients in such rare tumors of children.

Conclusion

The EFT located in the chest wall are rare tumors in childhood with infiltrative growth patterns. Although they respond well to chemotherapy and radiotherapy, their clinical behavior is usually aggressive. With neoadjuvant chemotherapy, tumors shrink in most cases. Surgical management involves extensive resection of the chest wall components, lung and/or diaphragm and the reconstruction of the defect with graft material. Despite total resection, negative surgical margins are seldom reached. Local recurrences and metastasis are associated with poor prognosis. Multicenter studies should be planned in order to better understand the nature of this rare patient group.

Ethics

Ethics Committee Approval: This study was approved by the Hacettepe University Non-interventional Clinical Research Ethics Board (approval no.: 2022/22-10, date: 27.12.2022).

Informed Consent: Retrospective study.

Authorship Contributions

Surgical and Medical Practices: İ.R.U., B.A., F.Y., D.O., F.Ü., S.E., Concept: A.Ö.Ç., İ.K., Design: T.K., Data Collection and/or Processing: B.A., B.O., M.H., S.E., Analysis and/

or Interpretation: A.Ö.Ç., İ.K., B.O., M.H., D.O., F.Ü., S.E.,
Literature Search: İ.R.U., B.A., Writing: İ.R.U.

Conflict of Interest: The authors declare that there is no conflict of interest regarding the publication of this article.

Financial Disclosure: The authors disclose that this research study was not funded by any specific grants from public, commercial, or not-for-profit sectors. The study was conducted independently without any financial support or sponsorship that could potentially introduce bias or influence the research outcomes.

References

1. Sandler G, Hayes-Jordan A. Chest wall reconstruction after tumor resection. *Semin Pediatr Surg* 2018; 27:200-6.
2. Campbell K, Shulman D, Janeway KA, DuBois SG. Comparison of epidemiology, clinical features, and outcomes of patients with reported ewing sarcoma and PNET over 40 years justifies current WHO classification and treatment approaches. *Sarcoma* 2018; 2018:1712964.
3. Stachelek GC, Ligon JA, Vogel J, et al. Predictors of recurrence and patterns of initial failure in localized ewing sarcoma: a contemporary 20-year experience. *Sarcoma* 2021; 2021:6681741.
4. Lopez C, Correa A, Vaporciyan A, Austin M, Rice D, Hayes-Jordan A. Outcomes of chest wall resections in pediatric sarcoma patients. *J Pediatr Surg* 2017; 52:109-14.
5. Maistry N, Durell J, Wilson S, Lakhoo K. Primary paediatric chest wall tumours necessitating surgical management. *Ann R Coll Surg Engl* 2020; 102:335-9.
6. Sanna S, Brandolini J, Pardolesi A, et al. Materials and techniques in chest wall reconstruction: a review. *J Vis Surg* 2017; 3:95.
7. Theodorou CM, Lawrence YS, Brown EG. Chest wall reconstruction in pediatric patients with chest wall tumors: a systematic review. *J Pediatr Surg* 2023; 58:1368-74.
8. Saltsman JA, Danzer E, Hammond WJ, et al. Survival and scoliosis following resection of chest wall tumors in children and adolescents: a single-center retrospective analysis. *Ann Surg* 2021; 274:e167-73.
9. Collaud S, Stork T, Dirksen U, et al. Surgical treatment for primary chest wall sarcoma: a single-institution study. *J Surg Res* 2021; 260:149-54.